Erythema Multiforme, Stevens–Johnson Syndrome, and Toxic Epidermal Necrolysis

20

Wolfram Hötzenecker, Anna Oschmann and Lars E. French

Chapter Contents

Erythema Multiforme 339
Stevens–Johnson Syndrome and Toxic Epidermal Necrolysis 344

ERYTHEMA MULTIFORME

Synonym: ■ Erythema multiforme minor – erythema multiforme von Hebra

Key features

- A self-limited but potentially recurrent disease
- Abrupt onset of papular "target" lesions, with the vast majority of lesions appearing within 24 hours
- Two types of target lesions are recognized: (1) typical, with at least three different zones; and (2) atypical papular, with only two different zones and/or a poorly defined border
- Target lesions favor acrofacial sites
- Erythema multiforme minor: typical and/or occasionally atypical papular target lesions with little or no mucosal involvement and no systemic symptoms
- Erythema multiforme major: typical and/or occasionally atypical papular target lesions with severe mucosal involvement and systemic features
- A preceding herpes simplex virus (HSV) infection is the most common precipitating factor; occasionally, there are other preceding infections or, rarely, drug exposure
- Diagnosis of erythema multiforme requires clinicopathologic correlation and is not based solely on histologic findings
- Erythema multiforme does not carry the risk of progressing to toxic epidermal necrolysis

Introduction

Erythema multiforme (EM) is an acute, self-limited skin disease characterized by the abrupt onset of symmetric fixed red papules, some of which evolve into typical and/or occasionally "atypical" papular target lesions[1,2]. The eruption is often precipitated by an infection, particularly HSV. Two forms of EM are recognized – EM minor and EM major. Both are characterized by the same type of elementary lesions (targets), but are distinguished by the presence or absence of mucosal involvement and systemic symptoms (Table 20.1). In the vast majority of patients, EM can be distinguished clinically from Stevens–Johnson syndrome (SJS) and toxic epidermal necrolysis (TEN) based upon the type of elementary skin lesions and their distribution[2,3].

History

EM was first described by the Austrian dermatologist Ferdinand von Hebra in 1860[4,5]. The disease he described was mild with a sudden onset of hundreds of red papules. By daily observation, von Hebra recognized that some of the original papules evolved into lesions with concentric zones of color change, which he termed "target" lesions. Some of the target lesions resembled a "herpes iris". However, von Hebra described neither a prodrome nor the presence of mucosal lesions. He recognized that the condition could be recurrent and mentioned a "typus annuus" which recurred every spring.

In 1950, Bernard Thomas further subdivided EM into EM minor and EM major[6]. Thomas considered von Hebra's disease to be EM minor, and severe mucosal necrosis with "EM-like" cutaneous lesions to be EM major. Since 1950, much confusion has developed regarding the definition of EM, in part because some authors, especially in the US, have stated that EM major includes SJS. However, recent investigations have clarified the situation by providing strong evidence that the term "EM minor" should be reserved for von Hebra's disease and the term "EM major" should be used for EM associated with mucosal lesions and systemic symptoms, but not for describing SJS, because SJS and EM major are distinct clinical disorders[2,3]. That said, because these are biologic processes, there can be patients where the distinction proves challenging.

Epidemiology

EM is predominantly observed in young adults and is very uncommon during childhood[3,7]. There is a slight male preponderance, but no racial predilection. The exact incidence rate of EM is not known.

Pathogenesis

Current understanding suggests that EM is most likely a mucocutaneous immune reaction that occurs in the setting of an infection in certain "predisposed" individuals. HSV is clearly the most commonly associated infectious agent, with *Mycoplasma pneumoniae* (which also may be associated with SJS), *Histoplasma capsulatum*, and parapoxvirus (orf) observed less frequently (Table 20.2)[8]. Histoplasmosis-associated EM may occur more often in patients with concomitant erythema nodosum. To date, evidence for EBV as a precipitating factor is inconclusive[7]. Rarely, EM has been associated with drugs or systemic disease (see Table 20.2). Consequently, the possibility of SJS, generalized bullous fixed drug eruption, polymorphous exanthematous drug eruption, or urticaria multiforme should be strongly considered if the presumed diagnosis is drug-induced EM[7,9]. Of note, several physical agents such as trauma, cold, and UV and orthovoltage irradiation have been described as triggers for outbreaks of EM related to infectious agents, drugs, or systemic disease.

To date, there is no clearly defined genetic predisposition for the development of EM. Several small studies of HLA alleles have found different associations: HLA-DQw3 (specifically the DQB1*301 split), DRw53, and Aw33[10,11]. These HLA associations differ from those reported for SJS and TEN (see below).

Herpes simplex virus and Mycoplasma pneumoniae

In the majority of children and adults with EM, the disease is precipitated by HSV types 1 and 2[12,13]. Preceding herpes labialis is noted in ~50% of patients with EM[12,13]. Herpes labialis may precede the onset of the cutaneous lesions, occur simultaneously, or be evident after the target lesions of EM have appeared. Most commonly, herpes labialis precedes target lesions of EM by 3–14 days. It is presumed that most cases in children and young adults are due to HSV type 1, but documented cases of HSV type 2 in adolescents and young adults have been reported[12,13].

Most of our current knowledge regarding EM is related to the study of HSV-associated EM. Not only are HSV-encoded proteins found within affected epidermis[12,13], but HSV DNA can be detected within the early red papules or the outer zone of target lesions in 80% of individuals with EM[5]. The presence of fragments of HSV DNA (most often comprised of sequences that encode its DNA polymerase) within the cutaneous lesions, as well as the expression of virally encoded antigens

Downloaded for Anonymous User (n/a) at Egyptian Knowledge Bank from ClinicalKey.com by Elsevier on March 10, 2024. For personal use only. No other uses without permission. Copyright ©2024. Elsevier Inc. All rights reserved.

COMPARISON OF ERYTHEMA MULTIFORME (EM) MINOR, EM MAJOR, STEVENS–JOHNSON SYNDROME (SJS), SJS/TOXIC EPIDERMAL NECROLYSIS (TEN) OVERLAP, AND TEN						
	Type of skin lesions	**Distribution**	**Mucosal involvement**	**Systemic symptoms**	**Progression to TEN**	**Precipitating factors**
EM minor (Fig. 20.1 & 20.2)	• Typical targets • ± *Papular* atypical targets	Extremities (especially elbows, knees, wrists, hands), face	Absent or mild	Absent	No	• Herpes simplex virus • Other infectious agents
EM major (Fig. 20.3)	• Typical targets • ± *Papular* atypical targets • Occasionally bullous lesions	Extremities, face	Severe	Usually present • Fever • Arthralgias	No	• Herpes simplex virus • *Mycoplasma pneumoniae* • Other infectious agents • Rarely, drugs
SJS (Fig. 20.7 & 20.14)	• Dusky and/or dusky red *macules* with epidermal detachment and erosions • *Macular* atypical targets • Bullous lesions • <10% BSA detachment	Isolated lesions Confluence (+) Trunk, face	Severe	Usually present • Fever • Lymphadenopathy • Hepatitis • Cytopenias	Possible	• Drugs • Occasionally, *Mycoplasma pneumoniae** • Rarely, immunizations
SJS/TEN overlap (Fig. 20.11)	• Similar to SJS • 10%–30% BSA detachment	Isolated lesions Confluence (++) Trunk, face, neck	Severe	• Same as SJS	Likely	• Drugs
TEN (Fig. 20.8 & 20.9)	• Similar to SJS • >30% BSA detachment	Confluence (+++) Isolated lesions rare Trunk, face, neck, elsewhere	Severe, with involvement of respiratory and gastrointestinal mucosa	• Same as SJS plus nephritis		• Drugs

*Occasionally, also subcorneal pustules.

Table 20.1 Comparison of erythema multiforme (EM) minor, EM major, Stevens–Johnson syndrome (SJS), SJS/toxic epidermal necrolysis (TEN) overlap, and TEN. BSA, body surface area; TEN, toxic epidermal necrolysis.

PRECIPITATING FACTORS IN ERYTHEMA MULTIFORME	
Infections (~90% of cases)	
Viral	• **Herpes simplex virus (HSV-1, HSV-2)** • Parapoxvirus (orf) • Vaccinia (smallpox vaccine) • Varicella zoster virus (chickenpox) • Adenovirus • Epstein–Barr virus • Cytomegalovirus • Hepatitis B & C viruses • Coxsackievirus • Parvovirus B19 • Human immunodeficiency virus
Bacterial	• ***Mycoplasma pneumoniae**** • *Chlamydophila* (formerly *Chlamydia*) *psittaci* (ornithosis) • *Salmonella* spp. • *Mycobacterium tuberculosis*
Fungal	• *Histoplasma capsulatum* • Dermatophytes
Drugs (unusual)	
Primarily	• Nonsteroidal anti-inflammatory drugs • Sulfonamides • Anticonvulsants, most commonly aromatic • Other antibiotics, e.g. aminopenicillins • Allopurinol
Exposures (unusual)	
	• Poison ivy • Vaccines (e.g. diphtheria & tetanus, hepatitis B virus)
Systemic disease (unusual to rare)	
	• Lupus erythematosus† (Rowell syndrome) • Inflammatory bowel disease • Behçet disease†

*Also precipitating factor for Stevens–Johnson syndrome and *Mycoplasma*-induced rash and mucositis (MIRM)/reactive infectious mucocutaneous eruption (RIME).
†May be a pattern of cutaneous lesions in the disease rather than a precipitating factor.

Table 20.2 Precipitating factors in erythema multiforme. This is a *non-exhaustive* list based primarily on case reports and small series of cases. The most common causes are in **bold**.

on keratinocytes, may be interpreted as evidence for replicating HSV within affected skin sites[12–14]. However, replication must be at a low level, because usually HSV cannot be cultured from EM lesions.

The inflammation within cutaneous lesions is believed to be a part of an HSV-specific host response[13]. Individuals with HSV-associated EM have normal immunity to HSV, but may have difficulty clearing the virus from infected cells; within sites of cutaneous lesions, HSV DNA may persist for 3 months after a lesion has healed[14]. Development of cutaneous lesions is initiated by the expression of HSV DNA sequences within the skin, followed by the recruitment of virus-specific T helper type 1 (Th1) cells that produce interferon-γ in response to viral antigens within the skin[15]. An "autoimmune" response is then thought to result from the recruitment of T cells that respond to autoantigens released by lysed/apoptotic viral antigen-containing cells. More recently it was shown that the HSV DNA fragments described above are transported (by peripheral blood $CD34^+$ Langerhans cell precursors) to the sites where EM skin lesions will develop prior to each eruption[16].

While HSV is the predominant cause of EM, there are other associated infectious agents. In particular, a severe acro-mucosal presentation with mucositis, conjunctivitis, and targetoid or bullous skin eruptions can be seen in patients with *M. pneumoniae* infections, primarily community-acquired pneumonia (see below). This variant occurs most commonly in young boys and adolescents. *M. pneumoniae* has been cultured from the bullae in patients with EM-like skin reactions, suggesting an etiologic role[17]. However, this association could also be explained by autoimmune molecular mimicry, as in *M. pneumoniae*-related Guillain–Barré syndrome[18].

Clinical Features

Due to a certain degree of clinical similarity, EM minor, EM major, SJS and TEN have, until recently, all been considered to be part of a single disease spectrum. However, as discussed previously, there is now strong evidence to support the concept that EM is a disease distinct from SJS and TEN at several levels – clinical, prognostic, and etiologic. Clinical criteria allow the distinction of both forms of EM from SJS/TEN in the vast majority of patients[2,3]. These clinical criteria are as follows: (1) the type of elementary skin lesion; (2) the distribution of skin lesions (topography); (3) the presence or absence of overt mucosal lesions; and (4) the presence or absence of systemic symptoms (see Table 20.1).

Downloaded for Anonymous User (n/a) at Egyptian Knowledge Bank from ClinicalKey.com by Elsevier on March 10, 2024. For personal use only. No other uses without permission. Copyright ©2024. Elsevier Inc. All rights reserved.

Elementary skin lesions (Fig. 20.1)

The characteristic elementary skin lesion of EM is the *typical target lesion*. The latter measures <3 cm in diameter, has a regular round shape and a well-defined border, and consists of at least three distinct zones, e.g. two concentric rings of color change surrounding a central circular zone that has evidence of damage to the epidermis in the form of bulla formation or crust[2]. Frequently, this central circular zone has a dusky appearance and over time, the lesion may resemble a "bull's eye".

While early target lesions often have a central dusky zone and a red outer zone ("iris" lesion), they can evolve to three zones of color change. Each concentric ring within the target lesion most likely represents one of a sequence of events of the same ongoing pathologic process. This may explain why some patients have only a limited number of fully developed, typical targets amidst a number of target lesions that are not yet typical or fully evolved, while in others all the lesions are at the same stage of development, thus creating a monomorphic clinical appearance. Given the possibility that only a few typical target lesions may be present, a complete skin examination is essential.

In EM, elevated *atypical papular target lesions* can either accompany typical target lesions or constitute the primary cutaneous lesion. These particular lesions are defined as round, edematous, palpable, and reminiscent of EM, but with only two zones and/or a poorly defined border. They must be distinguished from the flat (macular) atypical targets that are seen in SJS or TEN, but not EM. These macular lesions are defined as round lesions that are also reminiscent of EM, but with only two zones and/or a poorly defined border, as well as being non-palpable (with the exception of a potential central vesicle or bulla).

Distribution of skin lesions (topography)

Although there is considerable variation from individual to individual, numerous lesions are usually present[7]. In general, lesions of EM develop preferentially on the extremities and the *face*; target lesions favor the *upper extremities*, as does the entire eruption of EM[7,14,19]. The dorsal aspects of the hands and the forearms are the most frequently involved sites, but the palms, neck, face, and trunk are common locations as well (Fig. 20.2)[19]. Involvement of the legs is seen less frequently. EM lesions may also appear within areas of sunburn[7]. In addition, lesions tend to be grouped, especially on the elbows or knees.[7]

The Koebner phenomenon may be observed, with target lesions appearing within areas of cutaneous injury such as scratches[7] (see Fig. 20.1F) or as erythema and swelling of the proximal nail folds at sites of chronic self-trauma. The injury must precede the onset of the EM eruption because the Koebner phenomenon does not occur once the EM lesions have appeared.

Mucosal lesions

Severe mucosal involvement is characteristic of EM major. Mucosal involvement is usually absent in EM minor, and, when present, lesions are few in number and mildly symptomatic[3,7,12,13,19]. The primary mucosal lesions of EM are vesiculobullous and rapidly develop into painful erosions that involve the buccal mucosa and lips (Fig. 20.3), and less commonly the ocular and genital mucosae. On the lips, the erosions rapidly become covered by painful crusts. Erosions of the anogenital mucosa are often large and polycyclic with a moist base.

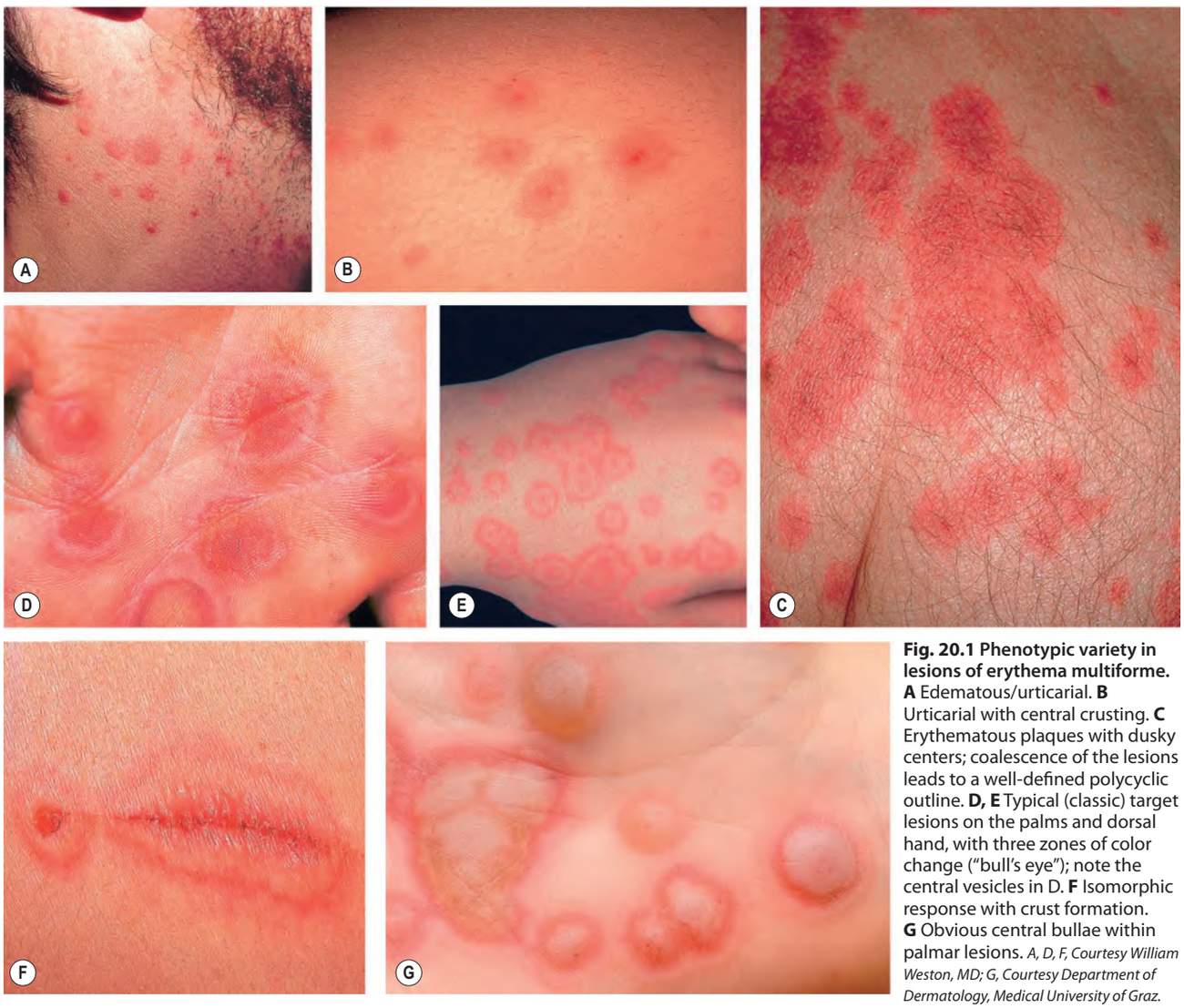

Fig. 20.1 Phenotypic variety in lesions of erythema multiforme. A Edematous/urticarial. **B** Urticarial with central crusting. **C** Erythematous plaques with dusky centers; coalescence of the lesions leads to a well-defined polycyclic outline. **D, E** Typical (classic) target lesions on the palms and dorsal hand, with three zones of color change ("bull's eye"); note the central vesicles in D. **F** Isomorphic response with crust formation. **G** Obvious central bullae within palmar lesions. *A, D, F, Courtesy William Weston, MD; G, Courtesy Department of Dermatology, Medical University of Graz.*

Downloaded for Anonymous User (n/a) at Egyptian Knowledge Bank from ClinicalKey.com by Elsevier on March 10, 2024. For personal use only. No other uses without permission. Copyright ©2024. Elsevier Inc. All rights reserved.

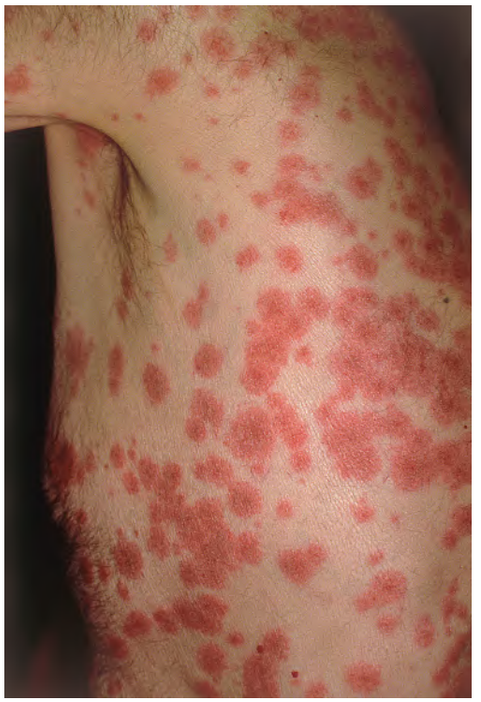

Fig. 20.2 Multiple lesions of erythema multiforme (EM) on the trunk. The dusky or crusted centers within the papules help to differentiate EM from a morbilliform drug eruption.

Fig. 20.3 Mucosal involvement in erythema multiforme major. A Typical target lesions are seen as well as serous crusting of the vermilion lips and eyelid margin. At the margin of the serous crusting of the lip, there are two zones of color with a polycyclic outline. **B** Erosions and hemorrhagic crusting of the lips in a child with the acro-mucosal variant associated with *Mycoplasma pneumoniae* infection, also referred to as MIRM (*Mycoplasma pneumoniae*-induced rash and mucositis) or RIME (reactive infectious mucocutaneous eruption). *B, Courtesy Julie V. Schaffer, MD.*

Systemic symptoms

Systemic symptoms are almost always present in EM major and absent or limited in EM minor. In EM major, the systemic symptoms that usually precede and accompany the skin lesions are fever and asthenia of varying degrees. Arthralgias with joint swelling have occasionally been described, as has pulmonary involvement resembling atypical pneumonia. Whether the latter is due to a pulmonary manifestation of EM versus an associated primary infection such as *Mycoplasma* pneumonia is unclear. Renal, hepatic, and hematologic abnormalities in the context of EM major are rare[20]. By integrating these four clinical criteria, a distinction can be made between EM minor, EM major, and SJS (see Table 20.1).

Natural history

In EM, almost all of the lesions appear within 24 hours and full development has occurred by 72 hours.[7,20] Pruritic or burning sensations within the lesions may be described. Individual lesions remain fixed at the same site for 7 days or longer[4,5,21].

For most individuals with EM, the episode lasts 2 weeks and heals without sequelae[7,20]; one possible rare exception is ocular damage in the setting of EM major, which may occur if adequate eye care is not promptly instituted. Occasionally, postinflammatory hyper- or hypopigmentation is seen. Patients with EM usually have an uncomplicated clinical course, although recurrences, in the case of HSV-associated EM, are quite common[7,20]. One recurrence each spring, as described by von Hebra, may occur[4]. Most individuals with recurrent HSV-associated EM have one or two episodes a year, with an exception being patients receiving immunosuppressive drugs[20,22,23]. The use of immunosuppressive agents such as oral corticosteroids may be associated with more frequent and longer episodes of EM[7,20]. These individuals may have five or six episodes per year or even almost continuous overlapping disease in which one attack has not completely resolved before another occurs. The incidence of secondary bacterial infections also increases in the setting of prolonged corticosteroid use[7,20]. Rarely, patients experience persistent EM with a months-long protracted course.

Pathology

EM is a clinicopathologic, not a purely histologic, diagnosis. Histologic findings are characteristic, but not specific, and are most useful for excluding entities in the differential diagnosis such as lupus erythematosus (LE) and vasculitis[7,20,22]. In EM, the keratinocyte is the target of the inflammatory insult, with apoptosis of individual or clusters of keratinocytes being the earliest pathologic finding (Fig. 20.4)[22]. As the process evolves, mild spongiosis and focal vacuolar degeneration of basal keratinocytes are observed. Superficial dermal edema and a perivascular infiltrate of lymphocytes with exocytosis into the epidermis are also seen.

Immunofluorescence findings are nonspecific[7]. Granular deposits of IgM and C3 around superficial blood vessels and focally at the dermal–epidermal junction have been described. Specific HSV antigens have been detected within keratinocytes by immunofluorescence, and HSV genomic DNA has been detected by PCR amplification of skin biopsy specimens[12,14].

Compared to SJS, the dermal inflammation component is more prominent in EM and the epidermal "necrolysis" component is more discrete[24]. Large areas of full-thickness epidermal necrosis are not seen in EM.

Downloaded for Anonymous User (n/a) at Egyptian Knowledge Bank from ClinicalKey.com by Elsevier on March 10, 2024. For personal use only. No other uses without permission. Copyright ©2024. Elsevier Inc. All rights reserved.

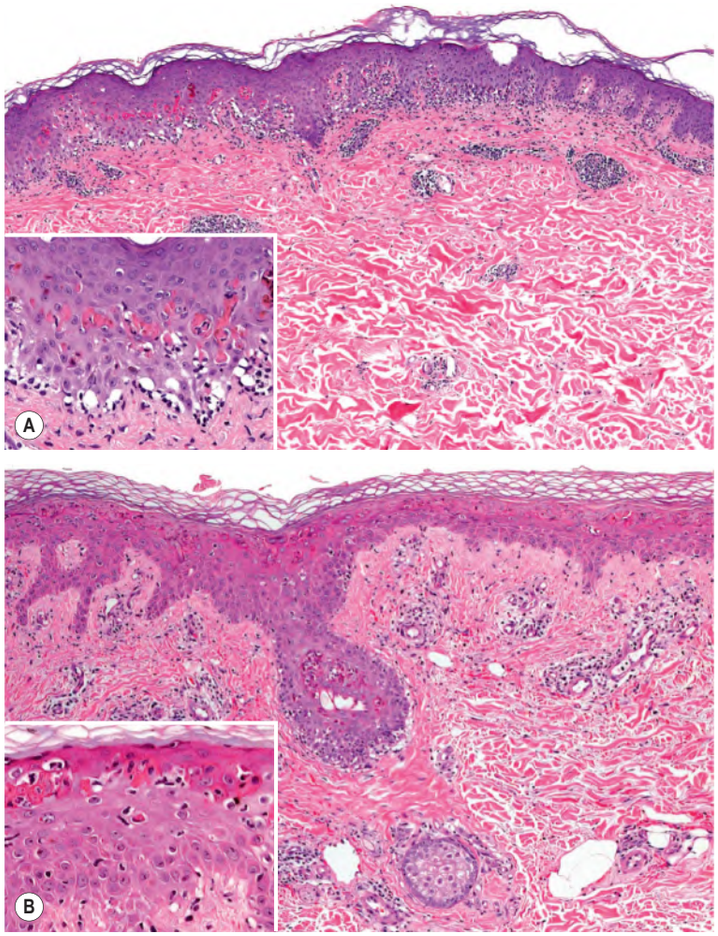

Fig. 20.4 Erythema multiforme – histopathologic features. A Early lesion – focal sites of apoptosis of keratinocytes with an interface dermatitis and vacuolar degeneration of the basal layer (inset). A perivascular lymphocytic infiltrate is also present. **B** Late lesion – more confluent necrosis of keratinocytes within the upper layers of the stratum spinosum (inset). The hair follicle still has evidence of an interface dermatitis. *Courtesy Lorenzo Cerroni, MD.*

Fig. 20.5 Acute annular urticaria (urticaria multiforme) in an infant misdiagnosed as erythema multiforme. These migratory, annular plaques are markedly edematous. Some of the lesions have an erythematous or dusky center while others have central clearing with two shades of peripheral rings. There are no crusts or blisters. The term "urticaria multiforme" has been used to describe these skin findings, which are often preceded by a viral or bacterial infection and accompanied by angioedema of the face, hands, and/or feet. *Courtesy Julie V. Schaffer, MD.*

COMPARISON OF URTICARIA AND ERYTHEMA MULTIFORME	
Urticaria	**Erythema multiforme**
Central zone is normal skin or transient duskiness*	Central zone is damaged skin (dusky, bullous, or crusted)
Individual lesions are transient, lasting <24 hours†	Individual lesions "fixed" for at least 7 days
New lesions appear daily	All lesions appear within first 72 hours
May be associated with swelling of face, hands, or feet (angioedema)	No edema
*May be referred to as urticaria multiforme. †Can be documented by circling individual lesions with ink then observing over time.	

Table 20.3 Comparison of urticaria and erythema multiforme.

Differential Diagnosis

Non-dermatologists often overdiagnose EM by labeling individuals with giant annular urticaria as having EM (Fig. 20.5)[9]. This is further highlighted by the term "urticaria multiforme", which represents a variant of urticaria that is often misdiagnosed as erythema multiforme or a serum sickness-like reaction in children[25]. This emphasizes the need to apply clinical criteria to distinguish EM from urticaria (Table 20.3)[7]. These include the presence of symmetrical fixed red papules or atypical papular target lesions, at least some of which evolve into typical target lesions. Particular attention should be given to the duration of individual lesions at a specific site and to epidermal damage in the center of the target lesions. EM papules are "fixed" at the same skin site for at least 7 days, whereas urticarial lesions last <24 hours at a particular site. The center of EM lesions demonstrates epithelial damage in the form of crusting or vesicles, whereas the center of giant urticaria is characterized by normal skin or erythema without epidermal damage. Administration of subcutaneous epinephrine (adrenaline) will clear urticaria within 20 minutes, but will not change EM lesions. Edema of the face, hands, and feet can be associated with urticaria, but is usually not observed in EM[7,9,20].

A number of other conditions can sometimes have "target-like" lesions and mimic EM, including fixed drug eruptions, Kawasaki disease, erythema annulare centrifugum, Sweet syndrome, and several forms of vasculitis[26]. A skin biopsy to exclude these entities is helpful. However, there is significant clinical and histologic overlap between EM and generalized bullous fixed drug eruption. The total number of lesions is helpful, especially when there are hundreds, but it is also important to try to determine the number of lesions present in the initial episode (i.e. fewer lesions in fixed drug eruption).

Recurrent EM during childhood may mimic polymorphous light eruption or juvenile spring eruption in that it may be sun-induced and develop with the first significant sun exposure in the spring[27]. In patients with systemic LE, occasional individual lesions can mimic true target lesions of EM, but other lesions characteristic of systemic LE are usually present[7]. That said, patients with Rowell syndrome may only have EM-like lesions as can children with Kawasaki disease. Early lesions of vasculitis, particularly urticarial vasculitis, may mimic target lesions of EM. Histologic examination assists in distinction; additional clues include an elevated ESR, autoantibodies, and low serum complement levels[7].

Whether *Mycoplasma pneumoniae*-induced rash and mucositis (MIRM) is a distinct disorder or within the spectrum of EM major or SJS remains a matter of debate (Table 20.4). More recently, as additional bacterial and viral triggers were identified, the term reactive infectious mucocutaneous eruption (RIME) was proposed[28].

Treatment

Therapeutic options include topical and systemic treatment of the acute eruption as well as prophylactic treatment of recurrent disease. Topical therapy includes topical antiseptics for eroded skin lesions and antiseptic/antihistamine rinses and local anesthetic solutions for oral lesions (see Ch. 72). Administration of topical ophthalmic preparations should be done in conjunction with an ophthalmologist.

There are no double-blind or open trials of systemic therapies for the acute episode of EM[7,20]. When a precipitating factor can be identified (e.g. HSV, *M. pneumoniae*), specific therapy should be instituted; in the case of HSV, this represents chronic suppressive antiviral therapy

Downloaded for Anonymous User (n/a) at Egyptian Knowledge Bank from ClinicalKey.com by Elsevier on March 10, 2024. For personal use only. No other uses without permission. Copyright ©2024. Elsevier Inc. All rights reserved.

KEY FEATURES OF *MYCOPLASMA PNEUMONIAE*-INDUCED RASH AND MUCOSITIS (MIRM)/ REACTIVE INFECTIOUS MUCOCUTANEOUS ERUPTION (RIME)
Children and adolescents >> adults
Prodromal symptoms (cough, malaise, fever) precede the eruptions by approximately one week
Predominance of mucosal involvement • Severe mucositis • Typically ≥2 mucosal sites (e.g. oral, ocular, anogenital, nasal) Absent or sparse polymorphic cutaneous involvement (<10% body surface area) • Typically vesiculobullous or atypical target lesions • Occasionally subcorneal pustules
For MIRM, clinical and/or laboratory evidence of *Mycoplasma pneumoniae* infection • PCR of pharyngeal swab • IgM and IgG serologies* For RIME, clinical and/or laboratory evidence of triggering infection, most often respiratory (see legend)
Often benign clinical course with excellent prognosis (<5% require intensive care but up to 10% may develop ocular sequelae) Supportive care and pain management similar to SJS with systemic antimicrobials if infectious trigger Systemic corticosteroids (e.g. 5–7 days of prednisone 1 mg/kg/day) – optional if severe†
*Serial measurements may be required to detect elevated IgM titers and are required to detect four-fold increase in IgG titers; enzyme-linked immunoabsorbent spot (ELISpot) assay of *Mycoplasma*-specific IgM antibody-secreting cells (ASCs) can improve diagnostic specificity and sensitivity. †Also case reports of etanercept, IVIg, and cyclosporine.

Table 20.4 Key features of *Mycoplasma pneumoniae*-induced rash and mucositis (MIRM)/reactive infectious mucocutaneous eruption (RIME). The terms MIRM then RIME were proposed to distinguish these infection-related eruptions from EM major and SJS/TEN. Prior to this distinction, patients were usually diagnosed as having incomplete, atypical or acro-mucosal SJS, *Mycoplasma*-associated EM major, *Mycoplasma*-associated SJS, Fuchs syndrome, or *Mycoplasma pneumoniae*-associated mucositis. Because other bacterial (e.g. *Chlamydophila pneumoniae*) and viral infections, especially respiratory (e.g. adenovirus, enteroviruses, human metapneumovirus, influenza B, parainfluenza virus type 2, rhinovirus, SARS-CoV-2), have been associated with similar mucocutaneous eruptions, this led to the term RIME. *Photographs: Courtesy Katherine G. Ligtenberg, MD, Jean L. Bolognia, MD, and Julie V. Schaffer, MD.*

(see below). As a rule, antiviral therapy has minimal impact if given after the appearance of the acute episode of EM. In most cases of EM, especially EM minor, symptomatic treatment will suffice. Oral antihistamines for 3 or 4 days may reduce the stinging and burning of the skin. In severe EM with functional impairment, early therapy with systemic corticosteroids (e.g. prednisone [0.5–1 mg/kg/day for 3–5 days] or pulse methylprednisolone [20 mg/kg/day for 3 days]) should be considered, despite the absence of controlled studies and the long-existing controversy regarding increasing the risk of infectious complications[29].

In individuals with HSV-associated EM with frequent recurrences, prophylaxis for at least 6 months with oral valacyclovir (500–1000 mg/day, with dose depending upon frequency of recurrences), famciclovir (250 mg twice daily), or acyclovir (10 mg/kg/day in divided doses) should be considered. A double-blind, placebo-controlled study in young adults with EM demonstrated the efficacy of acyclovir prophylaxis[23]. In addition to reducing the frequency of recurrences, occasionally the beneficial effect can continue even after the antiviral drug is discontinued. In non-responsive patients, the dose of the medication may be doubled, or a substitution made of the antiviral drug. However, as stated previously, treatment with acyclovir or valacyclovir after symptoms appear is ineffective[20]. Obviously, in those patients in whom EM is precipitated by factors other than reactivation of HSV, antivirals will be of no benefit.

In patients with recurrent EM that is resistant to prophylactic antiviral therapy, especially severe cases, several therapeutic approaches have been described; however, none have been validated by controlled trials and none have been consistently effective or free of side effects. Among these are: azathioprine (100 mg/day for several months), prednisone (0.5 mg/kg/day for several months), thalidomide, dapsone, cyclosporine, mycophenolate mofetil, and PUVA[20,30–33]. JAK inhibitors may be considered for persistent EM.

STEVENS–JOHNSON SYNDROME AND TOXIC EPIDERMAL NECROLYSIS

Synonym: ▪ Toxic epidermal necrolysis – Lyell syndrome

Key features

- Prodrome of upper respiratory tract symptoms, fever, and painful skin
- Stevens–Johnson syndrome (SJS) and toxic epidermal necrolysis (TEN) are two rare, potentially fatal, adverse cutaneous drug reactions of differing severity, characterized by mucocutaneous tenderness and erythema as well as extensive exfoliation
- SJS is characterized by <10% body surface area of epidermal detachment, SJS/TEN overlap by 10%–30%, and TEN by >30%
- The medications most frequently incriminated are allopurinol, nonsteroidal anti-inflammatory drugs, antibiotics, and aromatic anticonvulsants; TEN and SJS usually occur 7–21 days after initiation of the responsible drug
- The average mortality rate is 5% for SJS and 15%–25% for TEN; the mortality rates are often higher in the elderly and those with a very large surface area of epidermal detachment
- Exfoliation is due to extensive death of keratinocytes via apoptosis; the latter is mediated via the cytotoxic secretory protein granulysin and interaction of the death receptor–ligand pair Fas–FasL
- Optimal medical management of SJS and TEN requires early diagnosis, immediate discontinuation of the causative drug(s), and rapid initiation of supportive care
- Additional therapies include TNF inhibitors (e.g. etanercept), IVIg, cyclosporine, and pulse corticosteroids, but to date there is no consensus as to the most effective treatment

Introduction

Stevens–Johnson syndrome (SJS) and toxic epidermal necrolysis (TEN) are rare, acute, and life-threatening mucocutaneous diseases that are nearly always drug-related. They are a consequence of extensive keratinocyte cell death that results in the separation of significant areas of skin at the dermal–epidermal junction, producing the appearance of scalded skin. This extensive cell death also results in mucous membrane detachment, and it contributes to the characteristic symptoms of SJS and TEN, which include: high fever, moderate to severe skin pain, anxiety, and asthenia. The disease runs an unpredictable course. An initially benign-appearing dermatosis can progress rapidly, and once overt skin detachment has occurred, it is difficult to determine when it will end. Several studies have addressed the clinical signs of SJS and TEN, and there is now a framework of diagnostic criteria. Mortality risk can be calculated by applying a severity-of-illness score specifically developed for predicting the clinical outcome of TEN (SCORTEN; see below).

As prognosis is correlated with the speed at which the culprit drug is identified and withdrawn, it is crucial to establish the correct clinical diagnosis rapidly, so the causal drug(s) can be discontinued and appropriate medical treatment begun as soon as possible. Although TEN, and especially SJS, were historically considered to be part of a spectrum of diseases that included EM major (all of which have clinically similar mucosal lesions), these disorders should now be distinguished, as their cause, management, and/or prognosis are usually distinct (see Table 20.1). SJS and TEN should also be distinguished from dermatoses such as staphylococcal scalded skin syndrome, generalized bullous fixed drug eruption, drug-induced linear IgA bullous dermatosis, toxic erythema of chemotherapy, and acute generalized exanthematous pustulosis, as their management and prognosis can vary significantly.

Downloaded for Anonymous User (n/a) at Egyptian Knowledge Bank from ClinicalKey.com by Elsevier on March 10, 2024. For personal use only. No other uses without permission. Copyright ©2024. Elsevier Inc. All rights reserved.

High-quality supportive treatment, ideally in intensive care units with modern equipment and trained nursing staff, is the current standard of care and can improve outcome. To date, one randomized prospective trial has been conducted with 96 patients in which etanercept was compared to prednisolone (see below). The lack of additional large prospective, controlled clinical studies can be explained in part by the low incidence of SJS and TEN as well as their life-threatening potential which make randomized clinical trials difficult to perform.

History

In 1922, two US physicians, Stevens and Johnson, described an acute mucocutaneous syndrome in two young boys. The condition was characterized by severe purulent conjunctivitis, severe stomatitis with extensive mucosal necrosis, and "EM-like" cutaneous lesions. It became known as Stevens–Johnson syndrome (SJS) and was recognized as a severe mucocutaneous disease with a prolonged course and occasional fatalities[2,3]. SJS was later designated as EM major by Bernard Thomas in 1950.[6] However, recent clinical investigations have made it clear that the term "EM major" should not be used to describe SJS as they are distinct disorders (see Table 20.1)[2,3].

In 1956, Alan Lyell described four patients with an eruption "resembling scalding of the skin objectively and subjectively", which he called "toxic epidermal necrolysis". "Toxic" referred to toxemia – circulation of a toxin – which was thought to be responsible for the constitutional symptoms and epidermal necrosis. Lyell coined the term "necrolysis" by combining the key clinical feature "epidermolysis" with the characteristic histopathologic feature "necrosis". He also described an attack on the mucous membranes as part of the syndrome, and noted that there was very little inflammation in the dermis, a feature that was later referred to as "dermal silence"[34]. This feature contrasted with the obvious inflammatory infiltrate of other blistering disorders such as EM, dermatitis herpetiformis, and bullous pemphigoid. TEN was considered at the time to be a cutaneous reaction pattern to multiple stimuli, including drugs (e.g. sulfonamides) and microbes (e.g. *Staphylococcus*)[35].

The description of a subgranular epidermal split in neonatal mice following exposure to phage group II *S. aureus*, the subsequent discovery of a new staphylococcal exotoxin called epidermolytic toxin, and the absence of overt keratinocyte necrosis led to the distinction between TEN and what would come to be known as "staphylococcal scalded skin syndrome" (SSSS; see Ch. 74)[36]. It should be noted here that one of Lyell's original patients actually represented SSSS, and although by that time he had already noted the histologic differences between TEN and SSSS, they were attributed to different degrees of injury.

As more patients with TEN were reported in the years following Lyell's treatise, it became clear that certain drugs such as sulfonamides, pyrazolones (e.g. phenylbutazone), barbiturates, and aromatic anticonvulsants were principally associated with TEN. At the same time, drugs were increasingly being incriminated as a cause of EM associated with severe stomatitis. Hence, EM epidermal type (as defined by Orfanos et al.[37] in the mid 1970s), SJS and TEN were, at the time, considered to be part of a continuous spectrum of cutaneous reactions. It was clear, however, that HSV was the major cause of EM, and that this virus was not associated with cases of TEN. In the late 1990s, the group of Jean-Claude Roujeau clarified this issue by providing clinical evidence that EM and SJS were clinically distinct disorders with different causes and prognoses[3]. Increasingly, SJS and TEN are considered to be two ends of a spectrum of severe epidermolytic adverse cutaneous drug reactions, differing by the extent of skin detachment (see Table 20.1).

Epidemiology

SJS and TEN are rare diseases that affect women more often than men. Certain patient groups have an increased risk of developing SJS/TEN, including those who metabolize drugs at a decreased rate (slow acetylator genotypes), are immunocompromised (e.g. HIV infection), are undergoing radiotherapy while concomitantly receiving anticonvulsants, or have specific human leukocyte antigen (HLA) alleles (Table 20.5; see Table 21.3). Examples of the latter are HLA-B*15:02 in Asians and East Indians who are exposed to carbamazepine and HLA-B*58:01 in Han Chinese exposed to allopurinol. Consequently, the FDA recently recommended genotyping of all Asians for the allele HLA-B*15:02 prior to the administration of carbamazepine. In Europe, ~5% of the patients with SJS/TEN are infected with HIV[43].

STEVENS–JOHNSON SYNDROME (SJS) AND TOXIC EPIDERMAL NECROLYSIS (TEN): EPIDEMIOLOGY AND RISK FACTORS	
Annual incidence	1.2–6 per million (SJS)
	0.4–1.2 per million (TEN)
Ratio women : men	1.5 : 1
Risk factors	Slow acetylator genotypes
	Immunosuppression (e.g. HIV infection, lymphoma)
	Concomitant administration of radiotherapy and aromatic anticonvulsants (most commonly, those with brain tumors)
	HLA-B*15:02 – Asians (in particular Han Chinese, Thai, Malaysian populations)† and East Indians exposed to carbamazepine
	HLA-B*15:02 – Taiwanese/lamotrigine
	HLA-B*15:02 – Han Chinese/phenytoin
	HLA-A*31:01 – Europeans/carbamazepine
	HLA-B*58:01 – Han Chinese/allopurinol

†The background prevalence of HLA-B*15:02 varies from 4% to 15% in affected populations but is extremely rare in Northern Europeans (<0.01%).

Table 20.5 Stevens–Johnson syndrome (SJS) and toxic epidermal necrolysis (TEN): epidemiology and risk factors. Table 21.3 contains additional HLA associations. *Data from refs 38–42.*

Death rates reported in large case series in which only supportive therapy was used are quite variable, and it is known that these rates are heavily dependent on factors such as patient age and extent of epidermal detachment. In the past, mortality rates were reported to be ~10% for SJS, 30% for SJS/TEN, and 50% for TEN[43,44], but these rates have decreased over the past few decades. A USA-based study that analyzed nationwide inpatient records from 2009 to 2012 reported a mean mortality of 5%, 19%, and 15% for SJS, SJS/TEN, and TEN, respectively[45]. The mortality risk is lower in children who have TEN.

Use of medications is reported in over 95% of patients with TEN. A strong association between drug ingestion and development of the cutaneous eruption is observed in 80% of cases. Other rare causes include infections and immunizations. The literature reflects a less clear relationship between drugs and SJS, as only 50% of reported SJS cases are attributed to drug exposure. This is certainly an underestimation, however, and most likely is due, in part, to the confusion that previously existed regarding the diagnostic distinction between SJS and EM, especially EM major.

More than 100 drugs have been identified to date as being associated with SJS/TEN. The most frequently implicated drugs are listed in Table 20.6 and consist primarily of allopurinol, antibiotics, nonsteroidal anti-inflammatory drugs, and aromatic anticonvulsants. Among the antibiotics, sulfonamides are the most strongly associated with SJS/TEN; other antimicrobials include aminopenicillins, quinolones, cephalosporins, and tetracyclines as well as antiretrovirals. In general, the risk of developing SJS/TEN is reported to be highest during the initial week(s) of therapy. For the aromatic anticonvulsants, the risk is greatest during the first two months of treatment[46]. Furthermore, drugs with long half-lives are more likely to cause drug reactions and a fatal outcome than those with short half-lives, even if they are chemically related[47].

Pathogenesis

To date, the precise sequence of molecular and cellular events that lead to the development of SJS/TEN is only partially understood. The proposed pathogenesis must take into account the rarity of the reaction and the involvement of specific types of drugs.

Compelling evidence suggests that SJS/TEN is associated with an impaired capacity to detoxify reactive intermediate drug metabolites. It is thought to be initiated by an immune response to an antigenic complex formed by the reaction of such metabolites with certain host

Downloaded for Anonymous User (n/a) at Egyptian Knowledge Bank from ClinicalKey.com by Elsevier on March 10, 2024. For personal use only. No other uses without permission. Copyright ©2024. Elsevier Inc. All rights reserved.

MEDICATIONS MOST FREQUENTLY ASSOCIATED WITH STEVENS–JOHNSON SYNDROME AND TOXIC EPIDERMAL NECROLYSIS
• Allopurinol
• Aminopenicillins
• Amithiozone (thioacetazone)*,†
• Antiretroviral drugs, especially NNRTIs (e.g. nevirapine, efavirenz, etravirine)
• Barbiturates
• Carbamazepine
• Cephalosporins
• Chlormezanone*,‡
• Immune checkpoint inhibitors (e.g. ipilimumab, nivolumab)¶
• Phenytoin anticonvulsants
• Lamotrigine (risk may be increased when co-administered with valproic acid)
• Phenylbutazone*,§
• Piroxicam and other NSAIDs (e.g. diclofenac)
• Quinolones
• Sulfonamide antibiotics, including sulfamethoxazole‖, sulfadiazine*,†
• Sulfasalazine
*Not available in the US. †Antibacterial. ‡Sedative/hypnotic. ¶SJS/TEN-like eruptions may also occur with a delayed onset and favorable response to systemic corticosteroids. §Nonsteroidal anti-inflammatory drug. ‖Usually in combination with trimethoprim.

Table 20.6 Medications most frequently associated with Stevens–Johnson syndrome and toxic epidermal necrolysis. NNRTIs, non-nucleoside reverse transcriptase inhibitors. For a complete updated list of drugs associated with SJS and TEN, refer to: Shear N. *Litt´s Drug Eruption and Reaction Manual*, 28th edn. London: CRC Press, 2022.

tissues[44,48–50]. Currently, three different concepts exist regarding how the neoantigenic drug–tissue complex is formed: (1) covalent binding of the drug to a cellular peptide (hapten/pro-hapten concept); (2) non-covalent, direct interaction of the drug with a specific MHC class I molecule or T cell receptor (p-i concept); and (3) presentation of an altered-self repertoire by direct drug–MHC I molecule interaction (altered peptide concept). Whereas the well-known hapten model is less likely to be HLA-restricted, the other two concepts favor specific HLA phenotypes. According to these models, drugs directly bind to specific HLA molecules and/or T cell receptors without being processed by an antigen-presenting cell. In the p-i concept, the mere pharmacologic interaction of certain drugs with immune receptors is sufficient to elicit a drug hypersensitivity reaction[51]. In contrast, more recent reports have shown that the drugs abacavir and carbamazepine modify the HLA-peptide repertoire resulting in enhanced presentation of self-peptides and autoimmune reactivity (altered peptide model)[52,53]. Of note, because of the increased risk of DRESS, patients are often screened for HLA-B*57:01 prior to receiving abacavir (see Table 21.3).

In line with the concept of HLA-restricted drug presentation are reports of specific drug-related HLA alleles as major susceptibility genes for the development of SJS and TEN (see Table 20.5)[38,39,54]. Notably, in Taiwan, HLA-B*15:02 screening prior to administration of carbamazepine decreased the risk of drug-induced SJS/TEN[55]. In addition to the alleles listed in Table 20.5, the HLA-DQB1*06:01 allele has been reported in a significantly disproportionate number of White patients with SJS *and* ocular complications, suggesting that this allele may confer an increased risk for this specific clinical phenotype[56].

Cytotoxic T cells expressing the skin-homing receptor, cutaneous lymphocyte-associated antigen (CLA), are seen early in the development of cutaneous lesions[57]. These are likely to be drug-specific cytotoxic T cells[58]. Important cytokines such as interleukin (IL)-6, TNF, interferon-γ, IL-18, and Fas ligand (FasL) are also present in the lesional epidermis and/or blister fluid of patients with TEN, and their actions could explain some of the constitutional symptoms of TEN as well as the frequently observed discrepancy between the extent of epidermal damage and the paucity of the inflammatory infiltrate[59,60]. Lastly, the typical interval between the onset of drug therapy and SJS/TEN is between 1 and 3 weeks, suggesting a period of sensitization and providing further support for the role of the immune system in disease pathogenesis. This period ("memory") is considerably shortened in patients who are unfortunately re-exposed to a drug that previously resulted in SJS or TEN.

The tissue damage described by pathologists as epidermal necrolysis is a reflection of massive keratinocyte cell death via apoptosis[61]. The apoptosis of individual keratinocytes is a hallmark of the early stages of SJS and TEN, and it is the first clear morphologic sign of specific tissue damage. The more classic histologic image of extensive epidermal "necrolysis" is, in fact, the aftermath of keratinocyte apoptosis. Indeed, the apoptotic state of cells is transient in nature, and it is followed by necrosis if the apoptotic cells are not rapidly phagocytosed. In SJS and TEN, within hours keratinocyte apoptosis becomes very abundant in lesional skin, thus rapidly overwhelming the phagocytic capacity of the affected skin. Over a period of hours to days, these apoptotic keratinocytes become necrotic and lose their cohesion to adjacent keratinocytes as well as the basement membrane. The entire epidermis then loses viability, creating the familiar histologic image of full-thickness epidermal necrolysis.

Fas ligand (FasL, CD95L), a member of the TNF family of cytokines, has the ability to induce apoptosis by binding to its specific cell surface receptor, the Fas (CD95, Apo-1) death receptor[62]. Such death receptors function as cell surface sensors that detect the presence of specific extracellular death signals and rapidly trigger cellular destruction by apoptosis (Fig. 20.6, pathway A). Notably, keratinocyte apoptosis within lesional skin of patients with TEN is associated with highly increased expression of keratinocyte FasL, together with conserved levels of keratinocyte Fas expression[59,62–64]. Overlaying cryostat sections of lesional skin with Fas-sensitive cells as targets has demonstrated that keratinocyte FasL is cytolytically active in TEN; cytolysis can be prevented by monoclonal antibodies that block the interaction of Fas and FasL.

Subsequently, the cytotoxic molecule granulysin was shown to play a role in the keratinocyte apoptosis observed in SJS/TEN (see Fig. 20.6D)[65]. High concentrations of granulysin, a secreted, cationic, cytolytic protein produced by cytotoxic T lymphocytes (CTLs), natural killer (NK) cells, and natural killer T (NKT) cells, were found in blister fluid from patients with SJS/TEN. Moreover, injection of recombinant granulysin into mouse skin induced epidermal necrolysis and an inflammatory cell infiltrate. More recently, it was demonstrated that necroptosis of keratinocytes (a form of programmed necrosis) can be triggered by the interaction of annexin A1 and formyl peptide receptor 1 (FPR1) and this may contribute to the pathogenesis of SJS/TEN (see Fig. 20.6C).[66] In SJS/TEN patients, data suggest that exposure to the causative drug induces annexin A1 secretion from monocytes. Annexin A1 in turn binds to FPR1 and induces FPR1 expression in keratinocytes, resulting in cell death via a necroptosis pathway. Lastly, the perforin/granzyme pathway can also induce keratinocyte apoptosis (see Fig. 20.6B). Following the binding of CTLs and NK cells to their target cells, they secrete granules containing perforin and granzyme B. Perforin allows granzyme B to transverse the cell membrane and activate the intrinsic apoptotic pathway[67]. Of interest, circulating levels of IL-15 appear to be associated with the severity and mortality rate of SJS/TEN[68].

In summary, the current model for the pathogenesis of SJS/TEN is as follows: upon exposure to certain types of drugs (see Table 20.6), an individual with particular predisposing factors (see Table 20.5) mounts a specific immune reaction to the drug or one of its metabolites. As a result of an interplay of cell types and cytokines that remains to be totally defined, there is a strong expression of the cytolytic molecule FasL on keratinocytes as well as secretion of granulysin from CTLs, NK cells and NKT cells and annexin A1 from monocytes. This leads to FasL-, granzyme B-, and granulysin-mediated apoptosis and/or annexin-dependent necroptosis of keratinocytes and subsequent epidermal necrosis and detachment (see Fig. 20.6).

Clinical Features

Initial symptoms of both TEN and SJS can be fever, stinging eyes, and pain upon swallowing, any of which can precede cutaneous manifestations by 1 to 3 days. Skin lesions tend to appear first on the trunk, spreading to the neck, face, and proximal upper extremities. The distal portions of the arms as well as the legs are relatively spared, but the palms and soles can be an early site of involvement. Erythema and erosions of the buccal, ocular, and genital mucosae are present in >90% of patients (Fig. 20.7). The epithelium of the respiratory tract is involved in 25% of patients with TEN, and gastrointestinal lesions

Downloaded for Anonymous User (n/a) at Egyptian Knowledge Bank from ClinicalKey.com by Elsevier on March 10, 2024. For personal use only. No other uses without permission. Copyright ©2024. Elsevier Inc. All rights reserved.

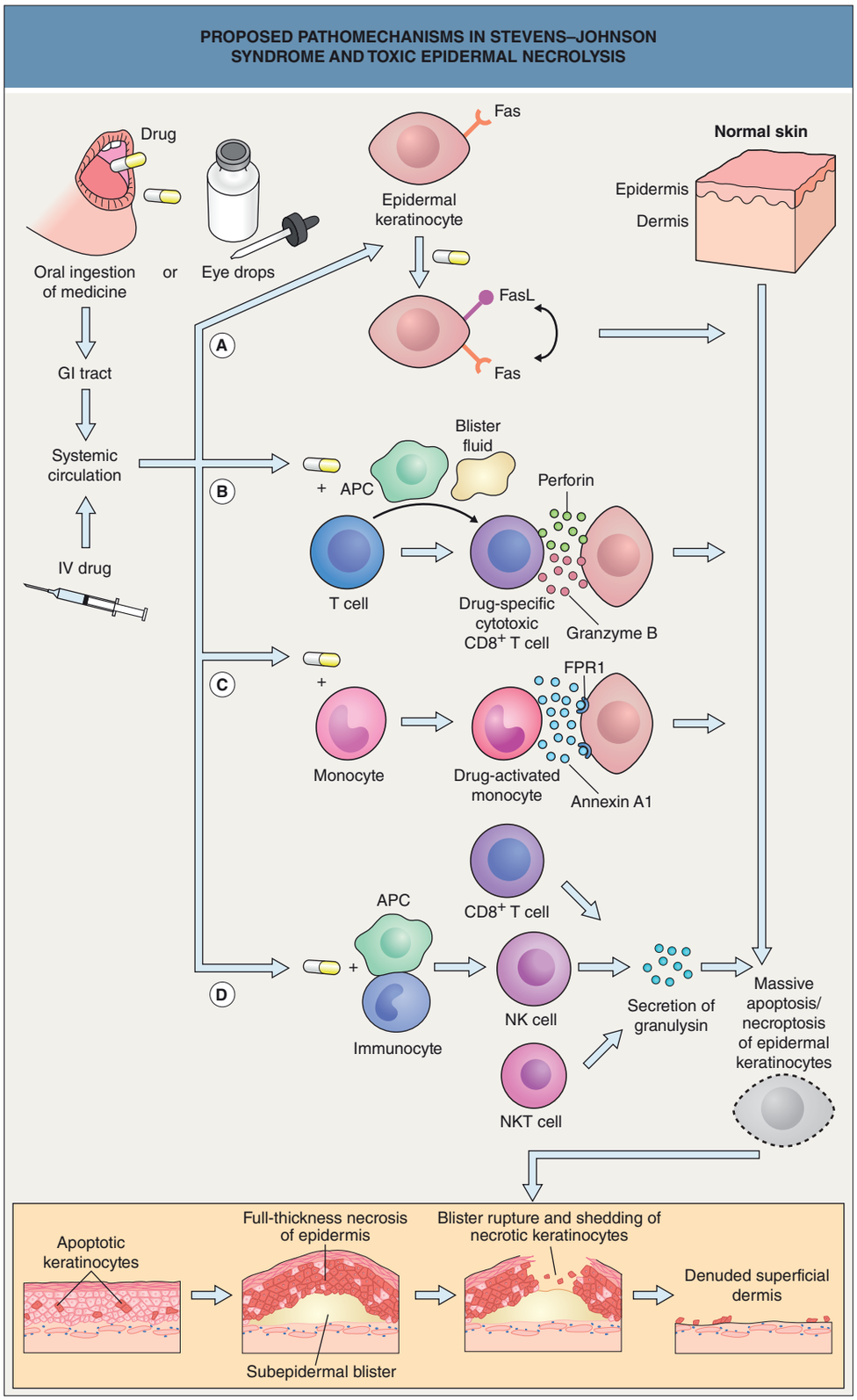

Fig. 20.6 Proposed pathomechanisms to explain apoptosis of epidermal keratinocytes in Stevens–Johnson syndrome (SJS) and toxic epidermal necrolysis (TEN). A number of medications can trigger widespread apoptosis of epidermal keratinocytes in individuals with SJS or TEN, leading to skin blistering and denudation. Several theories have been proposed for this condition: (**A**) the medication might induce upregulation of FasL by keratinocytes constitutively expressing Fas, leading to a death receptor-mediated apoptotic pathway; (**B**) the drug might interact with MHC class I-expressing cells and then drug-specific $CD8^+$ cytotoxic T cells accumulate within epidermal blisters, releasing perforin and granzyme B that kill keratinocytes; (**C**) drug-activated monocytes could secrete annexin A1, which induces necroptosis in keratinocytes via binding to formyl peptide receptor 1 (FPR1); and (**D**) the drug may also trigger the activation of $CD8^+$ T cells, NK cells and NKT cells to secrete granulysin, with keratinocyte death not requiring cell contact. IVIg contains antibodies against Fas that can block the binding of FasL to Fas. FPR1, formyl peptide receptor 1. *Adapted from Nickoloff BJ. Saving the skin from drug-induced detachment. Nat Med 2008;14:1311–13, with permission of Nature Publishing Group.*

(e.g. esophagitis, diarrhea) can also occur[69]. The skin lesions are usually tender, and mucosal erosions are very painful. Additional systemic manifestations include fever, lymphadenopathy, hepatitis, cytopenias, and cholestasis due to vanishing bile duct syndrome.

The morphology of the skin lesions has been studied in detail. First, lesions appear as erythematous, dusky red, or purpuric *macules* of irregular size and shape, and they have a tendency to coalesce (Fig. 20.8). At this stage, and in the presence of mucosal involvement and tenderness, the risk of rapid progression to SJS or TEN should be strongly suspected. In the absence of spontaneous epidermal detachment, a Nikolsky sign should be sought by exerting tangential mechanical pressure with a finger on several erythematous zones. This sign is considered positive if dermal–epidermal cleavage is induced. In some patients, the macular lesions observed at the onset can have a dusky center, giving them a target-like appearance. However, such lesions lack the three concentric rings characteristic of typical target lesions (as originally described by Hebra) and are not papular as in atypical target lesions of EM.

As the epidermal involvement progresses toward full-thickness necrosis, the dusky red macular lesions take on a characteristic gray hue. This process can be very rapid (hours), or take several days.

Downloaded for Anonymous User (n/a) at Egyptian Knowledge Bank from ClinicalKey.com by Elsevier on March 10, 2024. For personal use only. No other uses without permission. Copyright ©2024. Elsevier Inc. All rights reserved.

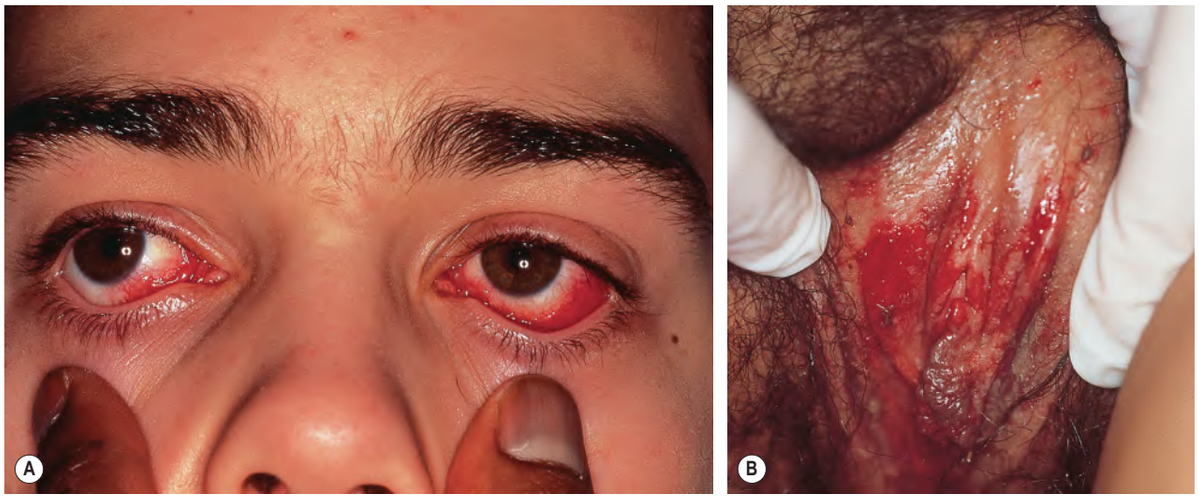

Fig. 20.7 Mucosal involvement in Stevens–Johnson syndrome. A Erythema and conjunctival erosions. **B** Erosions of the genital mucosa.

Fig. 20.8 Cutaneous features of toxic epidermal necrolysis (TEN). Characteristic dusky red color of the early macular eruption in TEN. Lesions with this color often progress to full-blown necrolytic lesions with dermal–epidermal detachment.

The necrotic epidermis then detaches from the underlying dermis, and fluid fills the space between the dermis and the epidermis, giving rise to bulla formation. The blisters have special features: they break easily (flaccid) and can be extended sideways by slight pressure of the thumb as more necrotic epidermis is displaced laterally (Asboe–Hansen sign). The skin resembles wet cigarette paper as it is pulled away by minimal trauma, often revealing large areas of raw and bleeding dermis, which is referred to as "scalding" (Fig. 20.9). These patients must therefore be handled with extreme care. Tense blisters are usually seen only on the palmoplantar surfaces, where the epidermis is thicker and, therefore, more resistant to mild trauma.

When evaluating such patients, the extent of necrolysis constitutes a major prognostic factor. The rules characteristically used to evaluate the surface area of thermal burns are appropriate for this purpose (see Ch. 88). Experience has shown that the extent of skin detachment is easily overestimated. Measurements should include detached and detachable epidermis (positive Nikolsky sign) but not purely erythematous areas (negative Nikolsky sign)[2]. The extent of skin detachment allows classification of the patient into one of three groups (Fig. 20.10; see Table 20.1):

- SJS: <10% of body surface area (BSA)
- SJS/TEN overlap (an intermediate category): 10%–30% of BSA (Fig. 20.11)
- TEN: >30% of BSA.

Mucosal erosions are present in >90% of patients (see above). Patients may describe photophobia and painful micturition.

It is also important to distinguish between SJS and EM, which are now considered to be different illnesses with different prognoses (see EM History)[3]. Their histologic features are similar and, therefore, not helpful in distinguishing between the two diseases. Differentiation is based primarily on clinical characteristics, especially the appearance of the target lesions and their distribution. To retain the diagnosis of EM, typical target lesions need to exist, whereas SJS should be considered if target lesions are atypical (see Table 20.1). Unfortunately, criteria for predicting which patients with SJS are likely to progress to TEN are currently unavailable. Recently, a case report form for SJS/TEN has been created by an NIH working group to help standardize the collection of patient information[70].

In TEN, factors correlated with poor outcome include increasing age and extent of epidermal detachment. In addition, the number of medications, elevation of serum urea, creatinine and glucose levels, neutropenia, lymphopenia, and thrombocytopenia have been statistically linked to poor outcome. Late withdrawal of the causative drug is also associated with a less favorable outcome. It has been estimated that prompt withdrawal of the offending drug reduces the risk of death by 30% per day[47]. SCORTEN is a severity-of-illness score for TEN, in which seven parameters with equal weight have been integrated to predict outcome (Table 20.7)[71]. However, one study suggested that it may underestimate mortality risk[73].

In 2019, a second mortality prediction model was introduced – the ABCD-10 score (*a*ge ≥50 years [1 point], serum *b*icarbonate level <20 mmol/l [1 point], active *c*ancer [2 points], *d*ialysis prior to admission [3 points], and epidermal detachment >*10%* body surface area [1 point]). Dialysis represented the strongest predictor of in-hospital mortality, but overall the predictability of the ABCD-10 score did not differ significantly from SCORTEN and needs further validation[72]. Recently, a cohort study involving 196 Asian patients suggested that SCORTEN was superior in predicting mortality rates when compared to ABCD-10[74].

On average, death occurs in every third patient with TEN, and it is mainly due to infections (*S. aureus* and *Pseudomonas aeruginosa*). Massive transepidermal fluid loss associated with electrolyte imbalance, inhibition of insulin secretion, insulin resistance, and onset of a hypercatabolic state can also be contributive factors. All these complications of TEN (that can also be observed in SJS) are best managed in intensive care units. They can unfortunately culminate in adult respiratory distress syndrome and multiple organ failure despite adequate supportive therapy.

Healing of areas of detached epidermis through re-epithelialization usually starts within days, and it is complete in most cases within 3 weeks. This process results from proliferation and migration of keratinocytes from "reservoir" sites, such as healthy epidermis surrounding denuded areas and hair follicles within the areas of detachment. Due to this conserved capacity for re-epithelialization, skin grafting is not required in SJS or TEN. Unfortunately, however, healing can be imperfect, and survivors may have both ocular (symblepharon, conjunctival synechiae, entropion, ingrowth of eyelashes) and cutaneous sequelae (scarring, dyspigmentation, eruptive melanocytic nevi), as well

Downloaded for Anonymous User (n/a) at Egyptian Knowledge Bank from ClinicalKey.com by Elsevier on March 10, 2024. For personal use only. No other uses without permission. Copyright ©2024. Elsevier Inc. All rights reserved.

Fig. 20.9 Clinical features of toxic epidermal necrolysis (TEN). A Detachment of large sheets of necrolytic epidermis (>30% body surface area), leading to extensive areas of denuded skin. A few intact bullae are still present. **B** Extensive symmetric hemorrhagic crusting of the face with areas of denudation. **C** Epidermal detachment of palmar skin. **D** Note the rolled and folded sheets of detached epidermis at the edge of denuded skin in addition to widespread erythema and intact bullae. *D, Courtesy Luis Requena, MD.*

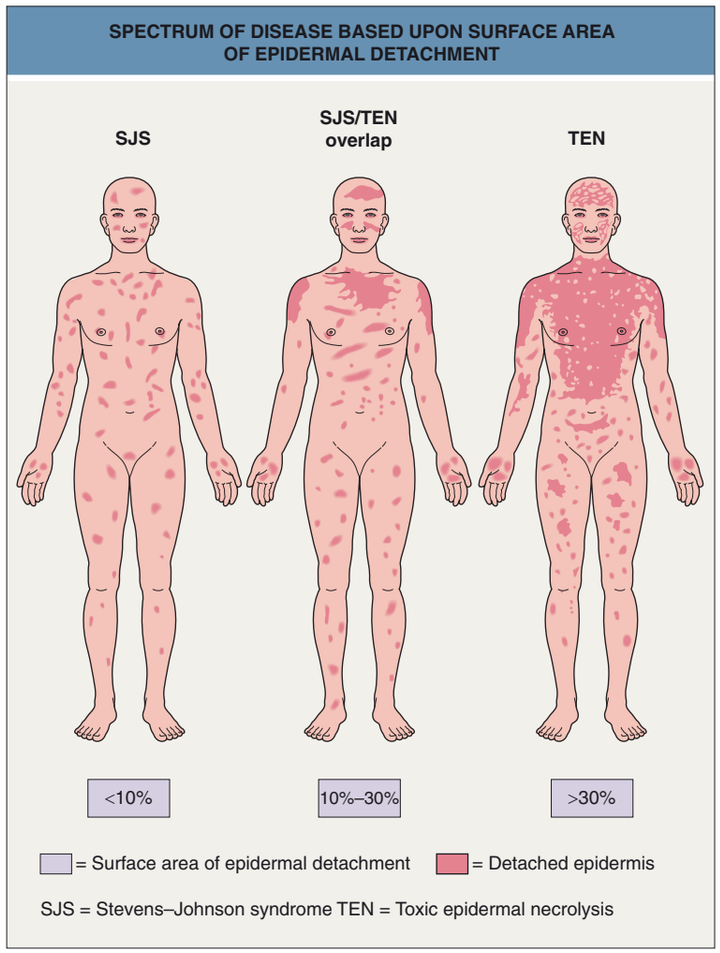

Fig. 20.10 Spectrum of disease based upon surface area of epidermal detachment.

as persistent erosions of the mucous membranes, urethral stenosis, phimosis, vaginal synechiae and stenosis with dyspareunia or hematocolpos, nail dystrophy, and diffuse hair loss (Fig. 20.12). These can often be minimized by optimizing skin care (see below), but, in TEN, up to 35% of survivors can have ocular symptoms ranging from sicca syndrome to blindness[44]. While amniotic membranes can be used acutely, scleral lenses (e.g. PROSE) assist in long-term care. Hypogeusia, dysphagia, progressive membranous glomerulonephritis, depression, and post-traumatic stress disorder represent additional sequelae.

Identification of the offending drug is an important and difficult task, but it should be among the first priorities. As noted previously, delayed withdrawal of the causative drug(s) is associated with increased mortality. Currently, there is no reliable *in vitro* test for the rapid identification of causative drugs. Patch testing shows weak sensitivity in SJS/TEN and is not appropriate for identification purposes; re-exposing the patient to the proposed causative drug is obviously not an acceptable option in severe drug reactions. The clinician, therefore, has to rely on previously reported associations and determine the probability (unlikely, possible, plausible, probable, very probable) for each medication based on the intrinsic ability of a particular drug to cause SJS/TEN (see Table 20.6 and reference therein) and extrinsic factors such as the initiation of a given medication with respect to the onset of SJS/TEN. SJS and TEN usually occur 7–21 days after initiation of the causative drug if it is the first exposure to the drug, but can occur within 2 days in the case of re-exposure to a drug that previously caused SJS or TEN. In general, the medication list of patients with SJS and TEN should be reduced to a strict minimum, appropriate substitutions made, and drugs with short half-lives favored. In an attempt to identify the culprit drug, ALDEN (algorithm of drug causality for epidermal necrolysis) and other causality assessment tools (CATs) have been developed which consider factors such as drug administration before and during disease progression, medication notoriety, and previous adverse reactions[75]. Unfortunately, available CATs, including ALDEN, have demonstrated poor reliability and validity[76].

Pathology

Histopathologic examination of lesional skin is a very useful tool for confirming the diagnosis of SJS and TEN, as the morphologic findings are distinct from those observed in SSSS (subcorneal blister with cleavage located in the granular layer of the epidermis) and acute generalized exanthematous pustulosis (AGEP; a neutrophil-rich infiltrate, superficial epidermal pustules and spongiosis, but no full-thickness epidermal necrolysis). Immediate analysis of frozen cryostat sections may be sufficient for this purpose.

Downloaded for Anonymous User (n/a) at Egyptian Knowledge Bank from ClinicalKey.com by Elsevier on March 10, 2024. For personal use only. No other uses without permission. Copyright ©2024. Elsevier Inc. All rights reserved.

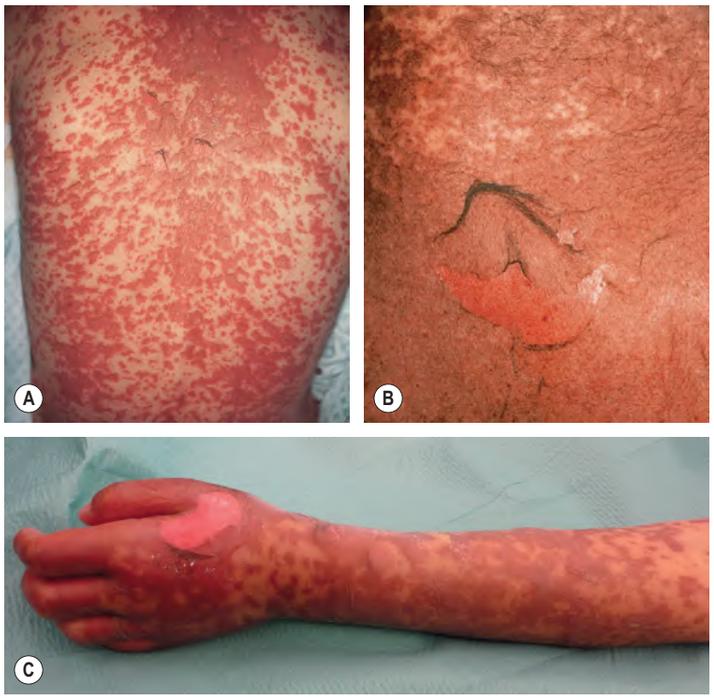

Fig. 20.11 Stevens–Johnson syndrome (SJS)/toxic epidermal necrolysis (TEN) overlap and early TEN. A In addition to mucosal involvement and numerous dusky lesions with flaccid bullae, there are areas of coalescence and multiple sites of epidermal detachment. Because the latter involved >10% body surface area, the patient was classified as having SJS/TEN overlap. **B** Close-up of epidermal detachment, the appearance of which has been likened to wet cigarette paper. **C** A child with early TEN due to diclofenac. There is coalescence of the dusky lesions as well as detached epidermis and denudation. *C, Courtesy Lisa Weibel, MD.*

SCORTEN	
Prognostic factors	**Points**
Age ≥40 years*	1
Heart rate ≥120 bpm	1
Cancer or hematologic malignancy*	1
BSA involved on day 1 >10%*	1
Serum urea level (>10 mmol/l)	1
Serum bicarbonate level (<20 mmol/l)*	1
Serum glucose level (>14 mmol/l)	1
SCORTEN	**Mortality rate (%)**
0–1	3.2
2	12.1
3	35.8
4	58.3
≥5	90

*Parameters also included in the ABCD-10 scoring system, but age ≥50 years, 2 points for active cancer, and 3 points for dialysis prior to admission. The predicted mortality rates varied from 2.3% (score = 0) to 84% (score = 6)[72].

Table 20.7 SCORTEN. A prognostic scoring system for patients with toxic epidermal necrolysis. The score is based upon seven prognostic factors. Some investigators also determine the red cell distribution width to hemoglobin ratio. BSA, body surface area. *Adapted from ref 71.*

In early lesions of SJS and TEN, apoptotic keratinocytes are observed scattered in the basal and immediate suprabasal layers of the epidermis (Fig. 20.13A). This is most likely the histologic correlate of the dusky to gray color that clinicians familiar with SJS/TEN consider as a warning sign of impending full-blown epidermal necrolysis and detachment. At later stages, lesional biopsy specimens show a subepidermal blister with overlying confluent necrosis of the entire epidermis and a sparse perivascular infiltrate composed primarily of lymphocytes (Fig. 20.13B). At an immunopathologic level, variable numbers of lymphocytes (usually $CD8^+$) and macrophages are observed within the epidermis, whereas lymphocytes in the papillary dermis are primarily $CD4^+$ cells[57].

Fig. 20.12 Sequelae of toxic epidermal necrolysis. A Symblepharon, erosion of lower lateral eyelid margin and sparse eyelashes; the patient also had entropion with an ingrowth of eyelashes and pebble-like scarring of facial skin. **B** Larger irregular areas of hypopigmented scarring. **C** Nail dystrophy consisting of longitudinal ridging and fissuring, fragility, and distal notching.

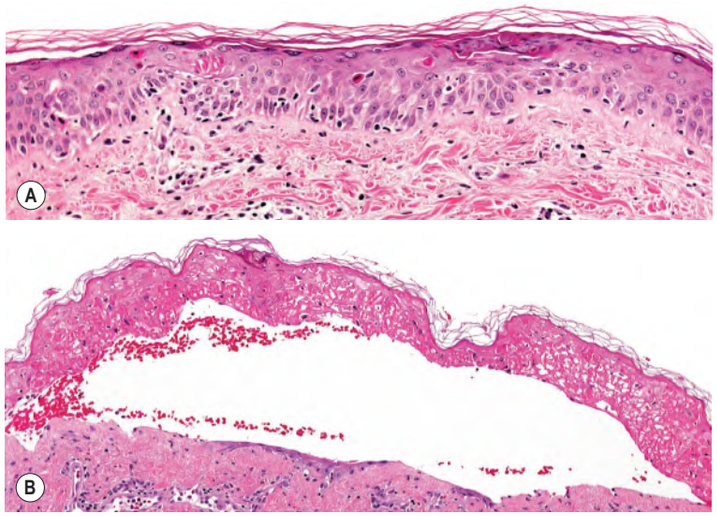

Fig. 20.13 Toxic epidermal necrolysis – histopathologic features. A Early lesions are characterized by apoptotic keratinocytes present individually and in clusters within the epidermis. Subtle vacuolar changes along the basal layer are accompanied by minimal inflammation, with scattered lymphocytes within the epidermis. **B** In later stages, a subepidermal blister with full-thickness necrosis of the overlying epidermis is seen. *Courtesy Lorenzo Cerroni, MD.*

Downloaded for Anonymous User (n/a) at Egyptian Knowledge Bank from ClinicalKey.com by Elsevier on March 10, 2024. For personal use only. No other uses without permission. Copyright ©2024. Elsevier Inc. All rights reserved.

DIFFERENTIAL DIAGNOSIS OF TOXIC EPIDERMAL NECROLYSIS	
Disease	**Clinical and histologic features**
Erythema multiforme and Stevens–Johnson syndrome	• See Table 20.1
Generalized bullous fixed drug eruption (see Ch. 21)	• When there are numerous mucocutaneous lesions • Timing post drug exposure differs • Microscopically, significant overlap
Acute generalized exanthematous pustulosis (AGEP; see Ch. 21)	• Numerous small, non-follicular pustules; can coalesce leading to large areas of exfoliation • Peripheral neutrophilia • *Microscopically, subcorneal pustules; no full-thickness epidermal necrosis*
Drug reaction with eosinophilia and systemic symptoms (DRESS; see Ch. 21)	• In addition to widespread erythema, vesiculobullae and pustules can develop • Facial edema; peripheral eosinophilia (most patients) • *Microscopically, changes are variable and sometimes nonspecific; necrosis usually absent; relatively dense dermal inflammatory infiltrate, often admixed with eosinophils*
Toxic erythema of chemotherapy (TEC; see Ch. 21)	• Exposure to particular chemotherapeutic or targeted agents • Symmetric dusky erythema, often involving skin folds, hands and feet and less often elbows and knees • Can be generalized but bullae less fragile • *Microscopically, usually minimal necrosis and presence of enlarged, atypical-appearing keratinocytes ("busulfan" cells)*
Drug-induced linear IgA bullous dermatosis (LABD), paraneoplastic pemphigus (PNP), bullous pemphigoid (see Chs. 29–31)	• Exposure to high-risk drugs, e.g. vancomycin for LABD • *Findings by routine histology and direct and indirect (PNP) immunofluorescence microscopy allow distinction*
Lupus erythematosus (Rowell syndrome; see Ch. 41)	• Usually resembles EM but can have TEN-like presentation • Appears *de novo* or as therapy tapered • Microscopically, significant overlap
Severe acute GVHD (stage/grade IV; see Ch. 52)	• Recipient of allogeneic hematopoietic stem cell transplant • Rare nowadays due to use of prophylactic GVHD therapies • Exposure to high-risk drugs for TEN and TEC is common • Microscopically, significant overlap
Staphylococcal scalded skin syndrome (SSSS; see Ch. 74)	• Children and occasionally adults • Split is more superficial so base is eroded epidermis not dermis • Perioral and periorbital accentuation with radial scale-crusts; no intraoral lesions • *Microscopically, subcorneal split with a normal underlying epidermis*
Invasive fungal dermatitis (see Ch. 34)	• Very-low-birth-weight newborns • Widespread erythema with erosions resembling a thermal burn • Usually due to candidal infection
Disseminated intravascular coagulation/purpura fulminans	• Bullae are hemorrhagic • Acral ischemia/necrosis • *Microscopically, fibrin thrombi within vessels in the dermis, with hemorrhage and minimal inflammation; necrosis of the epidermis, if present, is secondary to vascular occlusion*

Table 20.8 Differential diagnosis of toxic epidermal necrolysis. Distinctive histopathologic findings are in *italics*. In DRESS and AGEP, EM-like lesions can also be seen, including in the annular form of AGEP due to terbinafine.

Fig. 20.14 Early Stevens–Johnson syndrome. A In this child, there are individual erythematous lesions on the lower face, but coalescence on the cheeks. The two fresh bullae on the cheek are still intact. **B** This patient was originally diagnosed as a severe morbilliform drug eruption to penicillin, but then areas of epidermal detachment due to friction developed. *A, Courtesy Julie V. Schaffer, MD.*

Differential Diagnosis

The differential diagnosis of SJS consists primarily of EM (especially EM major), MIRM/RIME, autoimmune bullous diseases, and Kawasaki disease while the differential diagnosis for both SJS and TEN includes SSSS, drug-induced linear IgA bullous dermatosis (LABD), LE, generalized bullous fixed drug eruption, and the other entities outlined in Table 20.8. During the first 24–36 hours, SJS (as well as EM) may be diagnosed as a morbilliform drug reaction (Fig. 20.14).

Treatment

Optimal medical management of SJS and TEN requires early diagnosis, immediate discontinuation of the causative drug(s), and supportive care (Fig. 20.15).

Supportive care is similar to that performed for severe thermal burns, and it is aimed at limiting associated complications, which are the main cause of mortality. These include hypovolemia, electrolyte imbalance, renal insufficiency, and sepsis. Careful daily wound care, hydration, and nutritional support are essential and, preferably, done in an

Downloaded for Anonymous User (n/a) at Egyptian Knowledge Bank from ClinicalKey.com by Elsevier on March 10, 2024. For personal use only. No other uses without permission. Copyright ©2024. Elsevier Inc. All rights reserved.

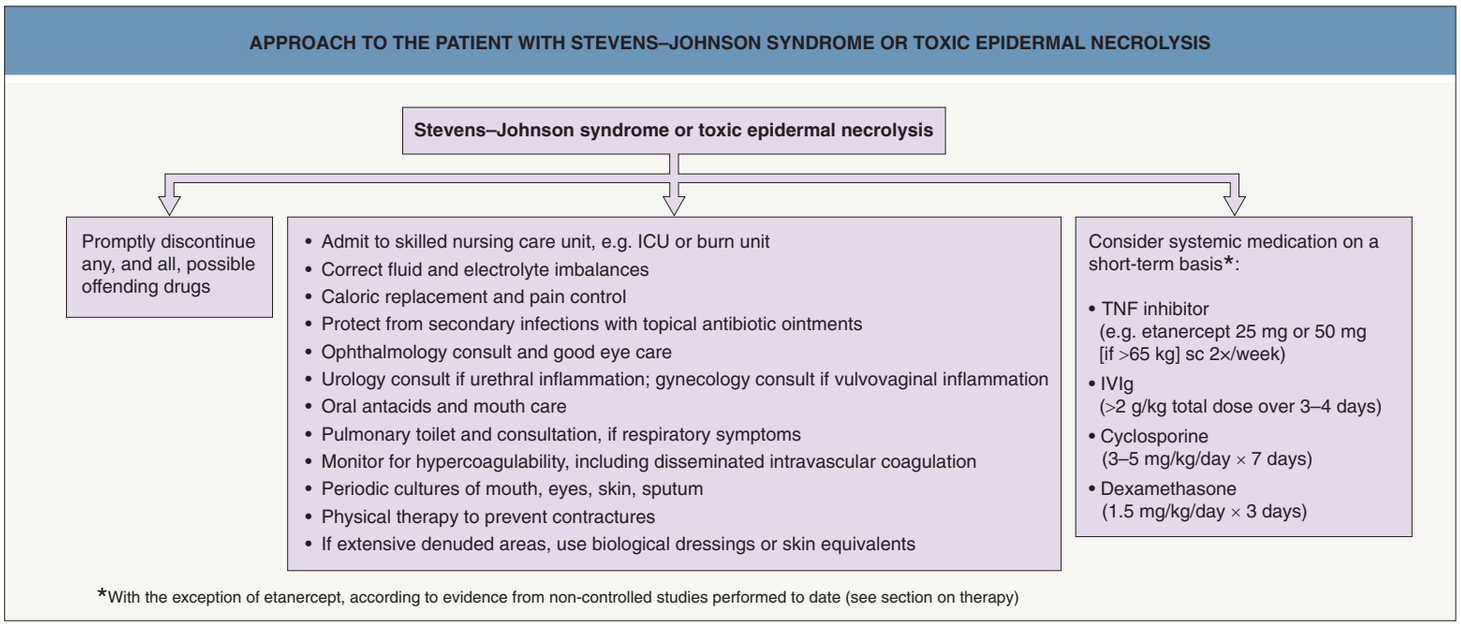

Fig. 20.15 Approach to the patient with Stevens–Johnson syndrome or toxic epidermal necrolysis. ICU, intensive care unit; sc, subcutaneous.

intensive care unit if there is epidermal detachment involving 10%–20% (or more) of BSA[77]. Use of a controlled pressure, thermoregulated bed and an aluminum survival sheet, instead of a regular bed and sheets, is recommended. All patient manipulations should be performed sterilely, and venous catheters should be placed, if possible, in a region of non-involved skin.

Wound care is best performed once daily with the help of, or in the presence of, a dermatologist. The patient should be manipulated as little as possible, as every movement is a potential cause of epidermal detachment. Cutaneous care should concentrate on the face, eyes, nose, mouth, ears, anogenital region, axillary folds, and interdigital spaces. Non-detached areas are kept dry and not manipulated. Detached areas, particularly on the back and pressure sites in contact with the bed, should be covered with Vaseline® gauze until re-epithelialization has occurred (see Ch. 145). For the face, serous and/or bloody crusts can be cleaned daily with isotonic sterile sodium chloride solution. An antibiotic ointment (e.g. mupirocin) or petrolatum ointment (if the patient is on systemic antibiotics) should be applied around orifices, e.g. ears, nose, mouth. Silicone dressings can be used to cover erosive denuded areas of skin. The silicone dressing does not need to be changed and can be left in place until re-epithelialization occurs, but its surface must be cleansed daily with isotonic sterile sodium chloride solution. Another option is to place a large non-adherent layered dressing (e.g. Exu-Dry™) over the patient and on the bed.

For the eyes, regular examination by an ophthalmologist is recommended. Eyelids should be gently cleansed daily with isotonic sterile sodium chloride solution, and an ophthalmic antibiotic ointment applied to the eyelids. In addition, antibiotic eyedrops should be administered three times a day to the cornea to reduce bacterial colonization, which can lead to scarring. Nostrils should be cleaned daily with a sterile cotton swab, moistened with isotonic sterile sodium chloride solution, and then the same procedure used to apply a little antibiotic (e.g. mupirocin) or petrolatum ointment. The mouth should be rinsed several times a day using a syringe with isotonic sterile sodium chloride solution, and then aspirated if the patient is unconscious. In the anogenital region and interdigital spaces, cutaneous care is performed daily by short applications of silver nitrate solution (0.5%) in the case of maceration, or simply sterile sodium chloride solution if there is no maceration.

In addition to supportive care, the most commonly employed systemic therapies have been TNF inhibitors, IVIg, cyclosporine, and corticosteroids. In a prospective, randomized, controlled trial involving 96 patients with SJS and TEN, etanercept was compared to intravenous prednisolone with the former resulting in shorter skin healing time (14 vs 19 days; $p = 0.01$) and less gastrointestinal hemorrhage[78]. However, to date, no additional large prospective, randomized, controlled clinical trials have been performed due in part to the low prevalence of these disorders. In general, therapy for severely affected patients with SJS has mirrored therapy for TEN, while those patients with milder non-progressive forms of SJS may receive only supportive care.

Although systemic corticosteroids have been a mainstay of therapy for decades, their use remains controversial[79]. A more recent study reported efficacy when the corticosteroids were administered acutely and over a short period of time as pulse therapy (intravenous dexamethasone 1.5 mg/kg for three consecutive days)[80]. In 2021, a network meta-analysis suggested that a combination of corticosteroids plus IVIg could reduce mortality in patients with SJS/TEN overlap and TEN[81]. Conflicting results have been observed with regard to the use of cyclosporine. A meta-analysis of 256 patients with SJS/TEN found significantly improved survival in patients treated with cyclosporine while a monocentric retrospective study of 174 patients did not see an advantage of cyclosporine over supportive care alone[82,83].

In 1998, IVIg was administered to a series of 10 patients, based upon the observation that IVIg contains antibodies that can block the binding of FasL to Fas (see Fig. 20.6A)[59]. High doses (0.75 g/kg/day for four consecutive days) were employed and blockage of the progression of epidermal detachment was observed[59]. Since then multiple published case series have been summarized in several meta-analyses[81,84–86]. While total doses of <2 g/kg may be insufficient for obtaining an optimal therapeutic effect[84], higher doses of IVIg (≥2 g/kg) correlated with an increased survival rate and lower mortality rate[85,87]. Relative contraindications for IVIg include a hypercoagulable state, IgA deficiency, and less so renal disease as the current products have less of an osmotic load.

In case reports and small uncontrolled series, several treatments have been reported as successful including cyclophosphamide (100–300 mg/day), plasmapheresis, and N-acetylcysteine (2 g/6 h)[88–90]. On the other hand, a controlled study using thalidomide was interrupted because of higher mortality in the thalidomide group compared with the placebo group[91].

Addressing the long-term complications of SJS/TEN clearly requires a multi-disciplinary approach.

Additional figures available in our eBook (see inside front cover for access code).

Downloaded for Anonymous User (n/a) at Egyptian Knowledge Bank from ClinicalKey.com by Elsevier on March 10, 2024. For personal use only. No other uses without permission. Copyright ©2024. Elsevier Inc. All rights reserved.

eFig. 20.1 Erythema multiforme-like lesions in two patients, one of whom had systemic lupus erythematous (A) and the other Sweet syndrome (B). *A, Courtesy Kalman Watsky, MD; B, Courtesy Dennis Cooper, MD.*

eFig. 20.3 Stevens–Johnson syndrome (SJS) due to ipilimumab that progressed to toxic epidermal necrolysis. The initial clue to the diagnosis of SJS was the fragility of the skin overlying the scapula (circled). *Courtesy Marianna Freudzon, MD.*

eFig. 20.4 Stevens–Johnson syndrome/toxic epidermal necrolysis overlap due to trimethoprim–sulfamethoxazole. Multiple dusky plaques with central blister formation that have coalesced on the mid and upper back. In the latter areas, the skin is fragile with obvious sloughing of the epidermis. *Courtesy Katherine Hunt, MD.*

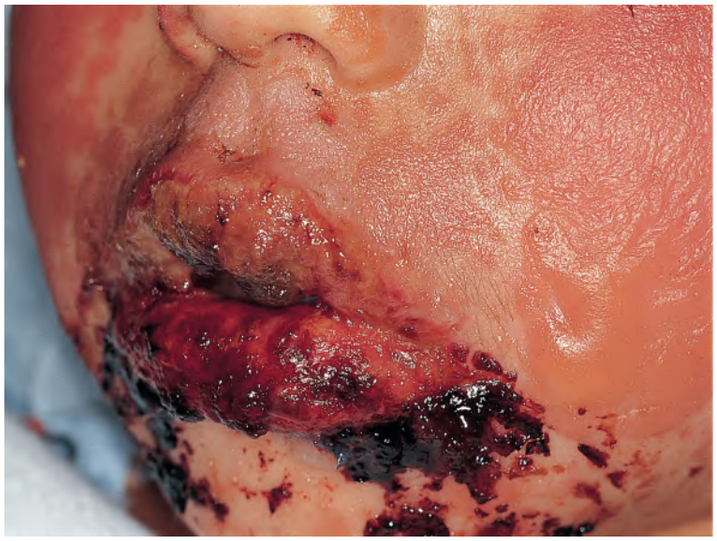

eFig. 20.2 Childhood Stevens–Johnson syndrome secondary to trimethoprim–sulfamethoxazole therapy. Note the hemorrhagic crusts and denudation of the lips as well as bullous cutaneous lesions. *Courtesy William Weston, MD.*

Downloaded for Anonymous User (n/a) at Egyptian Knowledge Bank from ClinicalKey.com by Elsevier on March 10, 2024. For personal use only. No other uses without permission. Copyright ©2024. Elsevier Inc. All rights reserved.

eFig. 20.5 Toxic epidermal necrolysis due to an antimalarial drug. The epidermis is no longer present on the majority of the back. *Courtesy Rosemarie Moser, MD.*

eFig. 20.6 Toxic epidermal necrolysis. Multiple hemorrhagic crusts with mucosal involvement.

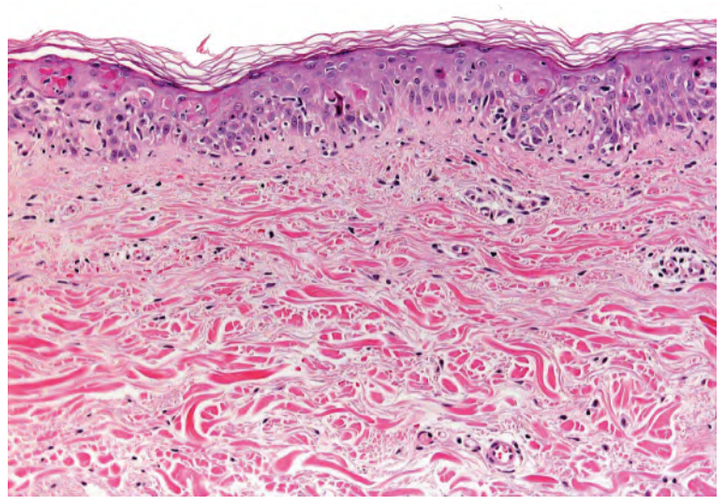

eFig. 20.7 Toxic epidermal necrolysis – histopathologic features. Early lesions are characterized by apoptotic keratinocytes present individually and in clusters within the epidermis. Subtle vacuolar changes along the basal layer are accompanied by minimal inflammation, with scattered lymphocytes within the epidermis. *Courtesy Lorenzo Cerroni, MD.*

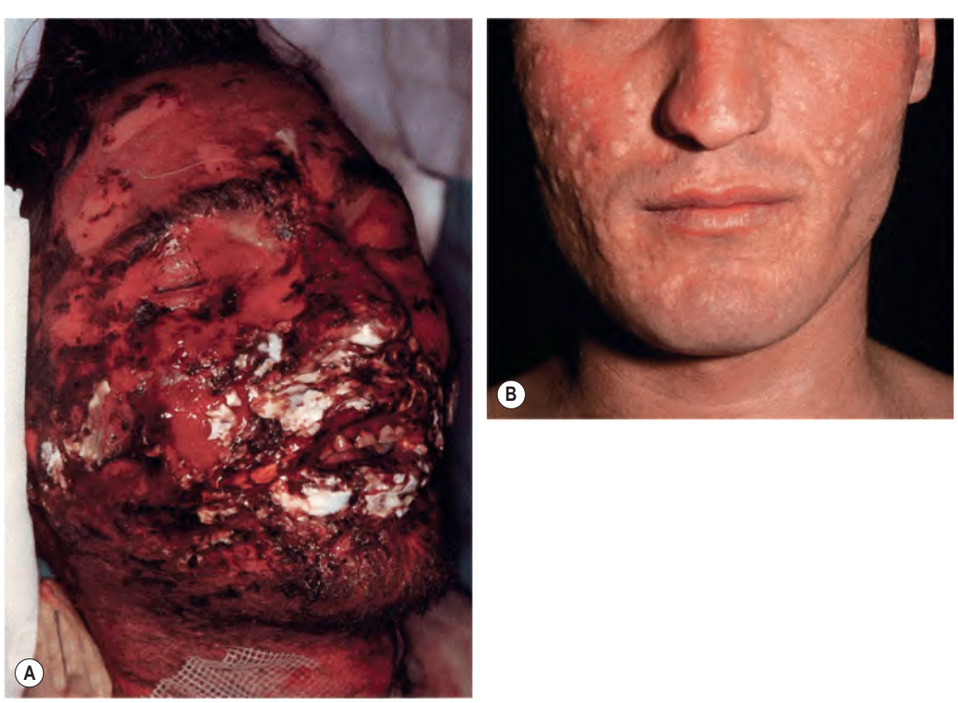

eFig. 20.8 Treatment of toxic epidermal necrolysis (TEN). Facial involvement of a patient with TEN (50% body surface area involvement) before (**A**) and 3 weeks after (**B**) treatment with IVIg (0.75 g/kg/day for 4 days).

Downloaded for Anonymous User (n/a) at Egyptian Knowledge Bank from ClinicalKey.com by Elsevier on March 10, 2024. For personal use only. No other uses without permission. Copyright ©2024. Elsevier Inc. All rights reserved.

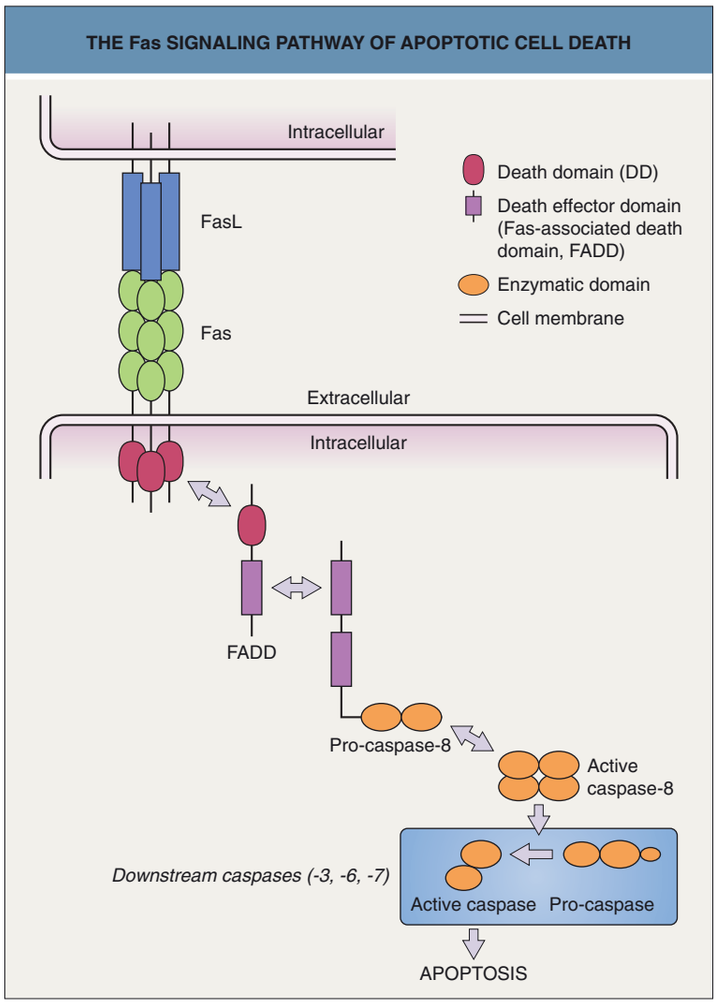

eFig. 20.9 The Fas signaling pathway of apoptotic cell death. The death receptor Fas and its ligand FasL are transmembrane proteins. Fas signaling is triggered in the target cells by receptor tri(multi)-merization, induced upon contact with membrane-bound FasL from an adjacent cell. Subsequently, recruitment of intracellular signaling proteins FADD and pro-caspase-8 leads to autoactivation of the protease caspase-8 as well as apoptosis due to subsequent activation of downstream effector caspases (caspases-3, -6, -7), which cause cellular disintegration and death. Stimuli that induce apoptosis include cellular stress, growth factor withdrawal, DNA damage and cytokines.

Downloaded for Anonymous User (n/a) at Egyptian Knowledge Bank from ClinicalKey.com by Elsevier on March 10, 2024. For personal use only. No other uses without permission. Copyright ©2024. Elsevier Inc. All rights reserved.